

CLINICAL APPLICATIONS

Reprinted from **Hugh E. Bateman** and **Robert M. Mason**

APPLIED ANATOMY AND PHYSIOLOGY OF THE SPEECH AND HEARING MECHANISM

Charles C. Thomas, Publisher, Springfield, Illinois, 1984

Chapter

20

FACIAL OSTEOTOMIES

GENERAL CONSIDERATIONS

THE modern oral and maxillofacial surgeon has the capability of surgically placing the jaws in virtually any new position. Individuals who suffer functionally or cosmetically from a *skeletal dysplasia* (abnormality of development) can benefit from surgery on the upper or lower jaw or both. Surgery is usually designed to provide a more functional dental arch relationship while also improving facial profile (cosmesis) (Fig. 20-1).

The general name for surgical repositioning of the jaws is an *osteotomy* (surgical cutting of a bone). In most facial osteotomies, some preoperative orthodontic treatment and postoperative orthodontic stabilizing treatment is required. Because of the collaborative contributions of the orthodontist and oral and maxillofacial surgeon, as well as a goal of surgery being the creation of a normal, straight (orthognathic) profile, the performance of facial osteotomies is usually referred to as *orthognathic surgery*.

The teeth usually adapt in some way to a dysplastic position of the jaws. Overgrowth of the mandible, or *prognathism*, for example, is usually accompanied by changes in the position of the upper and

lower incisor teeth. As the lower jaw grows forward, the lower incisors adapt by tipping the incisal edges backward (lingually) to maintain contact with the upper incisors. Likewise, the incisal edges of the maxillary incisors usually flare facially to some degree. As a result of this, orthodontic work preoperatively involves *decompensating* the dentition — that is, removing the natural compensations to the dentition that have occurred over time as the dysplastic jaw growth was experienced. The removal of the dental compensations prior to surgery permits the teeth and jaws to be arranged in a more stable position at the time of surgery. Most often, orthodontic treatment preoperatively increases the magnitude of the problem. In the case of mandibular prognathism, the lower anterior teeth are flared forward while the upper incisors are tucked back lingually. The surgical procedure, then, is designed to align the teeth appropriately, one arch to the other, by changing the position of the jaws (Fig. 20-2).

Orthognathic surgery has become a common and predictable endeavor. Most often, the planning for surgery is done

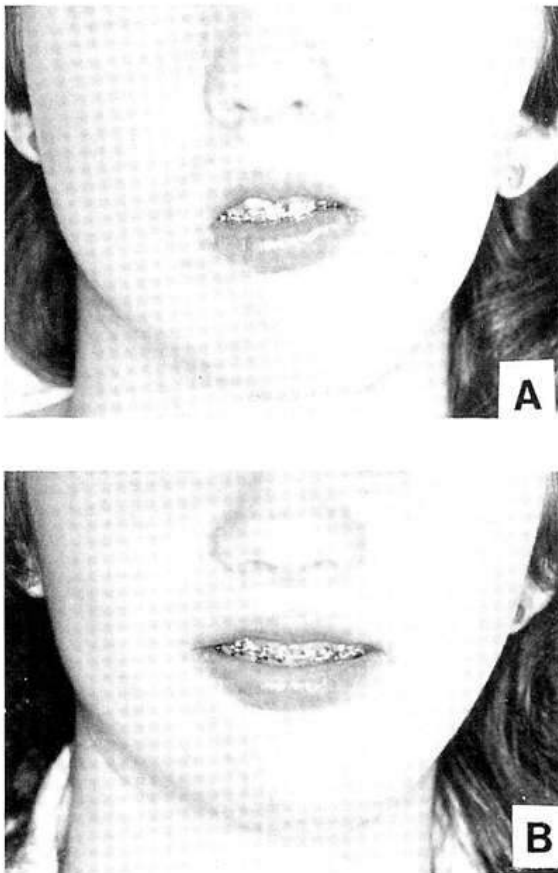


Figure 20-1. (A) 16-year-old patient with left hemifacial microsomia. The jaws were hypoplastic on the left side and the dental arches and supporting bone were malpositioned. The lower jaw deviated to the left. Both dental arches were “canted”; that is, tilted up on the left and down on the right. The patient is lip incompetent and shows 80 percent of upper tooth structure at rest. (B) Following maxillary impaction (8 mm up on the right) and rotation and uprighting of the mandible—combined maxillary and mandibular osteotomies.

mutually by an orthodontist and an oral and maxillofacial surgeon. In many instances, the orthodontist constructs the stabilizing acrylic splint utilized in surgery. Frequently, the orthodontist assists in surgery by placing the splint and wiring the jaws together. The splint is wired to the teeth by means of either orthodontic bands or archbars (metal bars wired to the teeth in surgery). Most surgical procedures in orthognathic surgery necessitate fixating

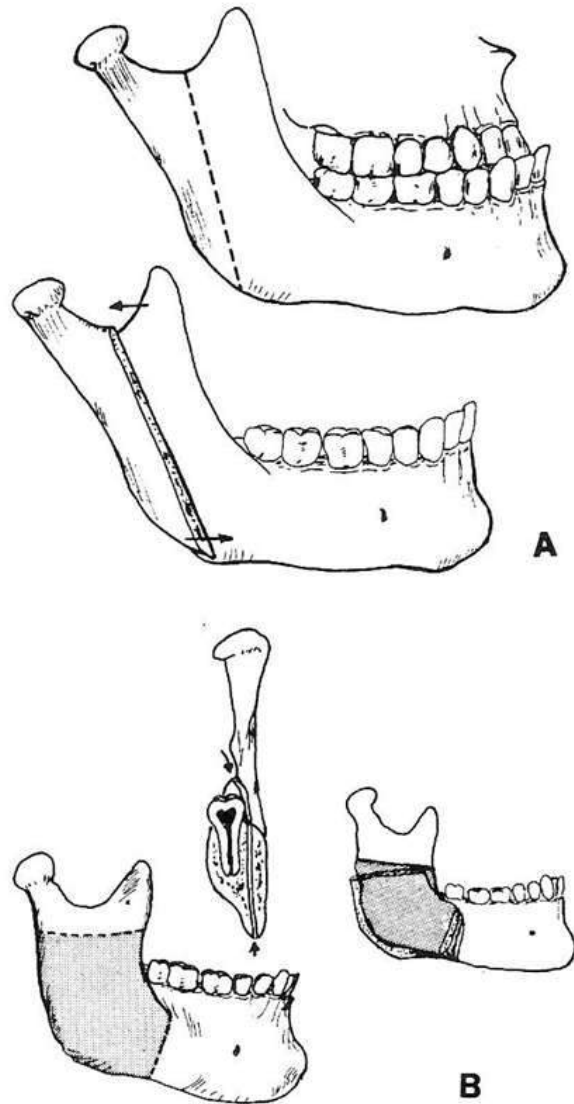


Figure 20-2. Mandibular osteotomies for prognathism. (A) Vertical oblique osteotomy, which can be done with an extraoral or intraoral approach. (B) A sagittal-split osteotomy, where cuts are made on the inside of the ramus and the outer surface of the body of the mandible.

the jaws in an immovable position for about six weeks to facilitate healing of the surgically modified jaw(s) position. Wiring the jaws closed as a part of surgery is called *intermaxillary fixation*. Such fixation is always utilized when one or both jaws have been moved surgically, while a partial or segmental osteotomy of a jaw may not require intermaxillary fixation.

MAXILLARY OSTEOTOMIES

An osteotomy to reposition the upper jaw, in most cases, referred to as a *LeFort osteotomy*, named after a French surgeon-anatomist, Rene LeFort. In 1900 and 1901, LeFort reported on experiments designed to illustrate the sites of fractures of the facial skeleton. These reports are now known as LeFort's classification of maxillary fractures. It is of general interest that LeFort's experiments involved whole cadavers. LeFort subjected the cadaver heads to a variety of traumatic blows, while varying the direction and force of the application. Afterward, the lines that the fracture patterns followed were carefully determined.

It is somewhat ironic that these early experiments have provided the modern surgeon with guidelines for the selection of surgical incisions for orthognathic procedures. The three basic patterns of facial fractures of the maxilla are now referred to as LeFort I, II, and III osteotomies.

A *LeFort I* osteotomy involves surgery to the alveolar process of the maxillae. The position of the teeth is changed, and there are also changes expected in the base of the nose, the upper lip, and in the nasal cavity. It might be expected that as the underlying bony framework is modified, adjacent soft tissues also change variably. The incisions for a LeFort I osteotomy are in the upper vestibule of the oral cavity, crossing the nasal floor, through the septum of the nose, and often at or near the anterior nasal spine (Fig. 20-3). The entire surgery is done intraorally.

The LeFort I osteotomy is the procedure of choice for advancing the lower portion of the maxilla (maxillary advancement), such as in an individual with a repaired cleft lip and palate who shows midfacial retrusion but who has acceptable orbits and cheek contours or projec-

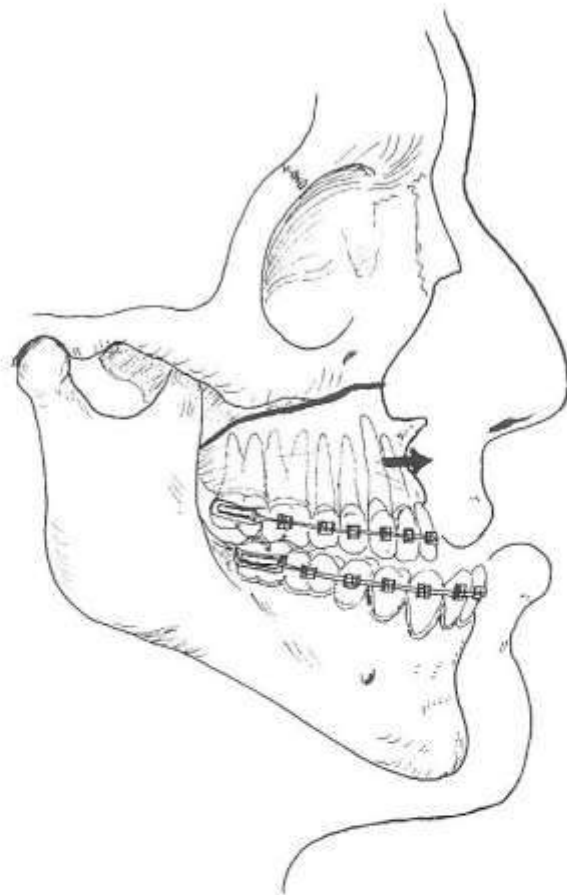


Figure 20-3. Drawing of a LeFort I maxillary osteotomy to advance the midface in a patient with maxillary retrusion and a repaired cleft lip and palate.

tions (Fig. 20-4). This operation is also suggested for the patient who has vertical maxillary excess with a toothy smile (vertically). A strip of bone is removed on both sides and the maxilla is repositioned superiorly in a *maxillary impaction* LeFort I osteotomy (Figs. 20-5, and 20-6A-D).

A partial or segmental osteotomy can be done to a portion of the dental arch, such as the surgical removal of first bicuspids and supporting bone at that area, and followed by retraction of the anterior dental and skeletal segment into the space created. Even a single tooth osteotomy

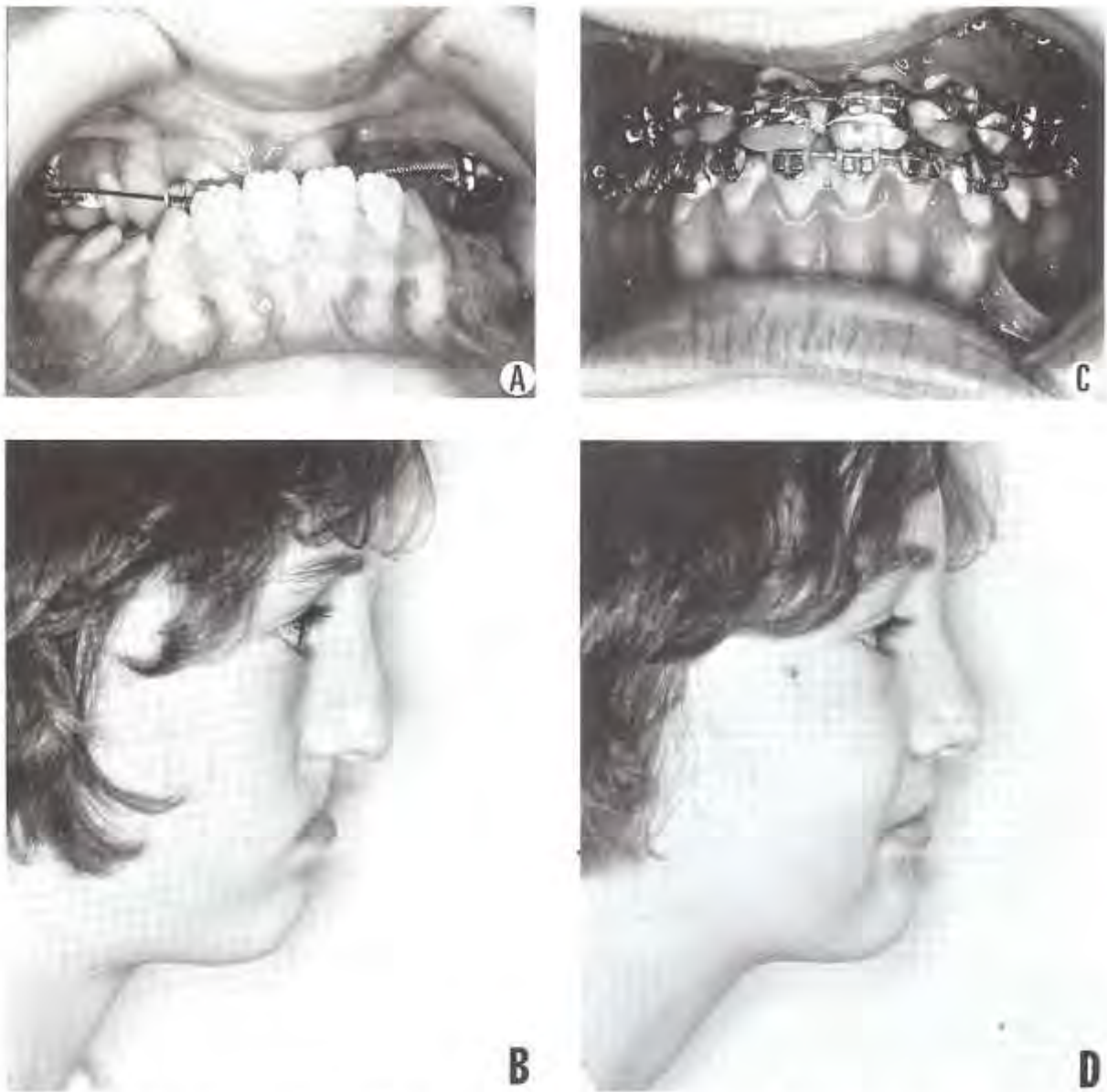


Figure 20-4. Dental occlusion and facial profile views of thirteen-year-old patient with a repaired cleft lip and palate who underwent a maxillary advancement osteotomy for midfacial retrusion.

can be done, although this would not be described as a LeFort osteotomy.

A *LeFort II* osteotomy is more extensive in its scope and in the vertical dimensions of the operation (Fig. 20-7). Incisions extend across the nasal bridge and across the orbital floor and lateral walls of the orbits. This procedure is indicated especially for a patient with midfa-

cial retrusion who also has flattening of the cheeks and orbital floor area. Hence, a *LeFort II* maxillary advancement can correct midfacial retrusion while simultaneously improving a flattened upper mid-face. Most of the surgery is done intra-orally on *LeFort II* osteotomies.

A *LeFort III* osteotomy is an extensive procedure used primarily with craniofacial

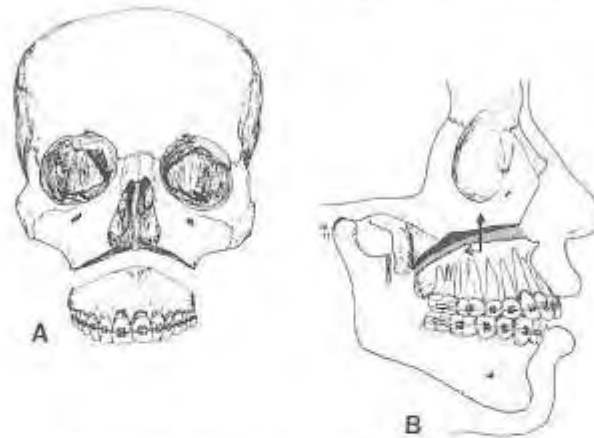


Figure 20-5. A LeFort I maxillary impaction for a patient with vertical maxillary excess. The stippled area of bone in B is removed by surgery (intraorally), and the maxilla is repositioned in a superior position. (A) Coronal view of the area where the maxilla is cut, (B) Lateral view.

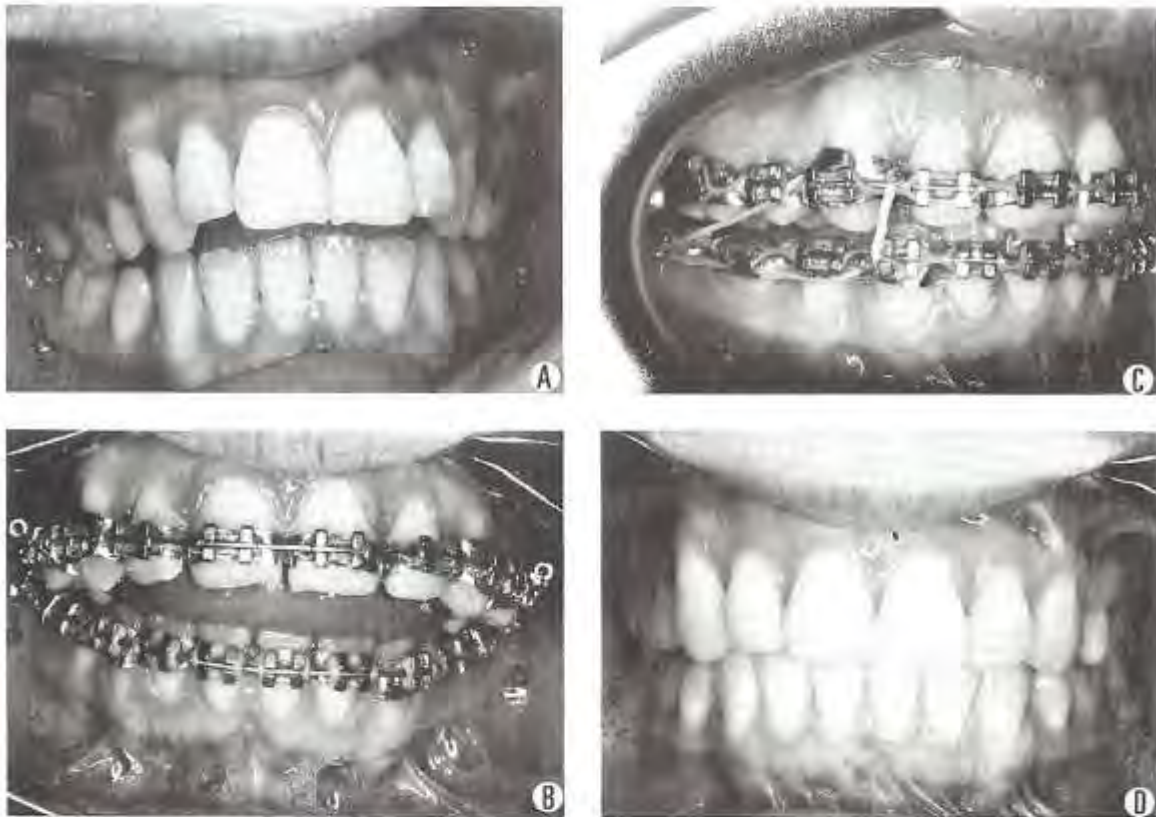


Figure 20-6. (A) Preoperative dental appearance of a patient with vertical maxillary excess. Due to the anterior openbite, the posterior portion of the maxilla needs to be surgically impacted more than the anterior part.

(B) Preoperative orthodontic treatment. The openbite increases as the arches are leveled, revealing the true extent of the deformity.

(C) Following surgery and release from intermaxillary fixation (jaws wired shut), light elastic forces are used to aid in stabilization and healing.

(D) The dental interdigitation following the completion of post-operative orthodontics.

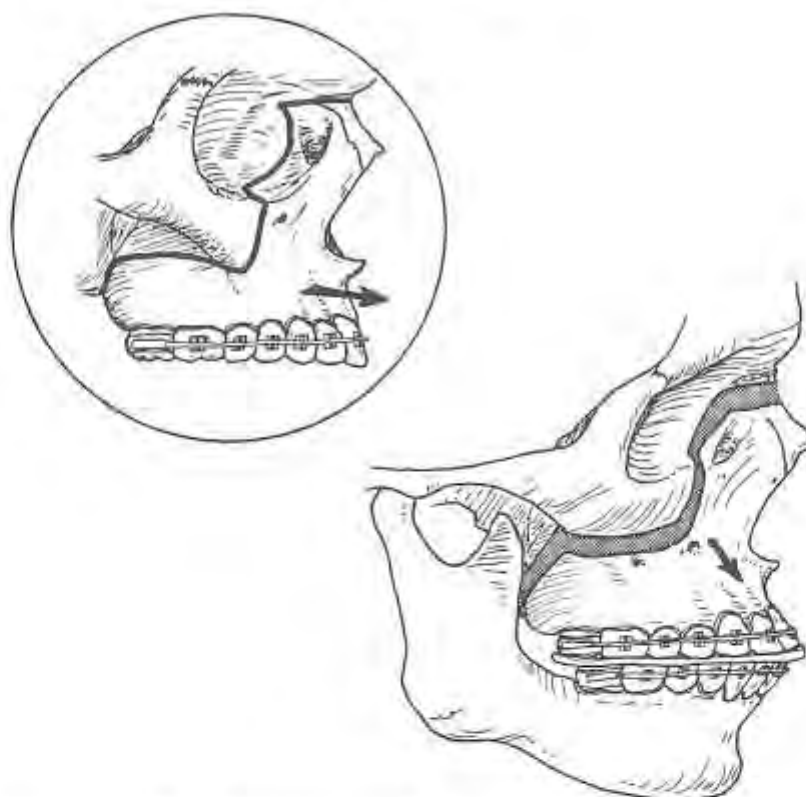


Figure 20-7. Drawing of a LeFort II osteotomy, which is used for midfacial advancement. Bone grafts are used to fill in the area where the advancement cuts are made.

syndrome patients such as Crouzon's, Apert's, and Pfeiffer's syndromes. Such patients usually have severe midface retrusion and other craniofacial variations. The LeFort III osteotomy mobilizes the entire maxillary-orbital structures and involves incisions across the vertex of the skull as part of the surgery (Fig. 20-8). Most of the surgery on the maxilla can be done intraorally.

The results of surgery can be extremely dramatic, especially since it is no longer rare to operate on both jaws and the chin (genioplasty) in the same procedure. Where two-jaw surgery is done in the same operation, it is common to employ two acrylic splints in surgery: (1) an intermediate splint to position the newly mobilized jaw via the unoperated jaw and (2) the final splint used in intermaxillary fixation. Needless to say, any osteotomy,

especially involving the maxilla, necessitates careful planning and coordinated efforts between surgeon and orthodontist.

Speech Implications from LeFort Osteotomies

The speech clinician should have some rudimentary knowledge of osteotomies, in that patients of mutual concern to the speech clinician and a variety of other specialists will undergo such procedures. Surgical advancement of the maxilla can potentially compromise the velopharyngeal mechanism and create hypernasality, especially in patients with repaired cleft palate where the adaptive capacity of the velum is reduced (Mason, Turvey, and Warren, 1980; Mason and Warren, 1981). In other patients, such as those with mid-

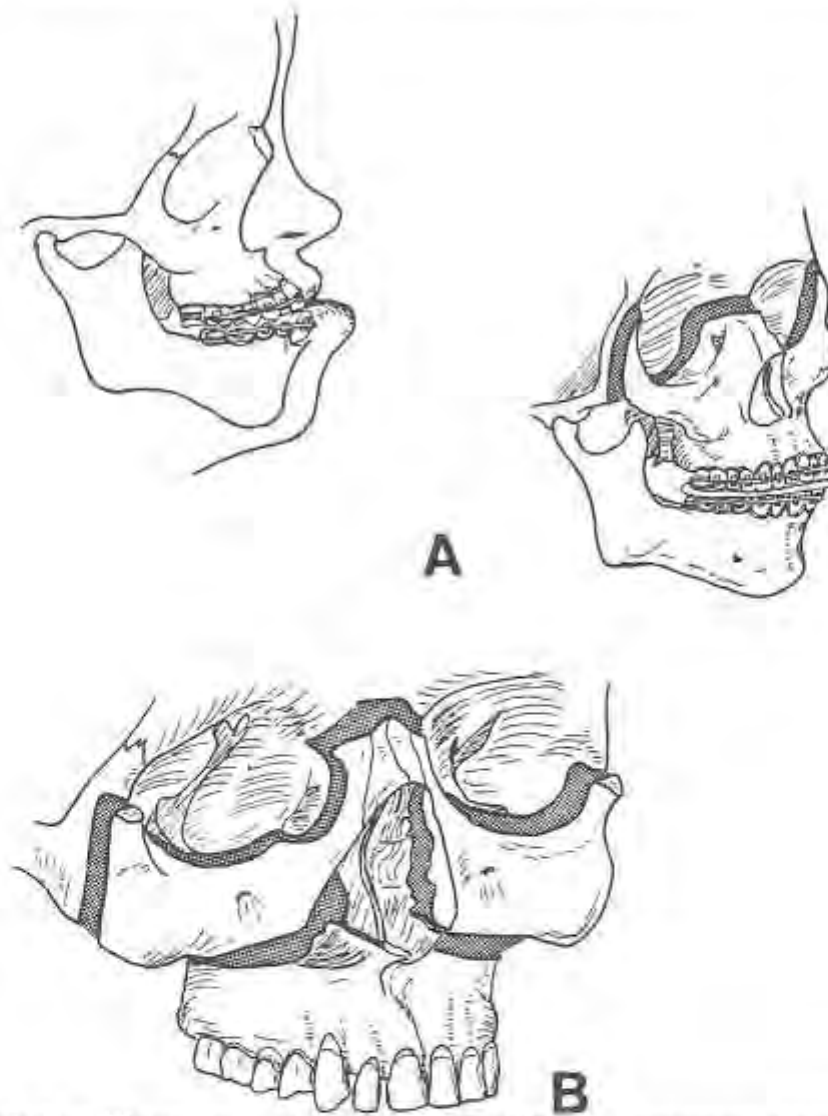


Figure 20-8. A LeFort III osteotomy, which is used for midfacial advancement in patients with severe midfacial retrusion. The entire maxillary-orbital structures are mobilized.

face retrusion syndromes (Crouzon's, Apert's, and Pfeiffer's), the nasopharyngeal area is very small prior to surgery, with a hyponasal voice quality. Following midfacial advancement surgery, speech is usually

seen to improve in nasal resonance balance. Thus, speech may improve spontaneously with surgical correction of a skeletal and dental malocclusion.

MANDIBULAR OSTEOTOMIES

Orthognathic surgery for the mandible may involve positioning the mandible up, down, back, forward, or any combination of positional changes. A genioplasty to

augment or decrease the chin prominence may be done in combination with a mandibular osteotomy.

A mandibular osteotomy for *prognath-*

ism involves separation of the two sides of the mandible at the angle and sliding the corpus of the mandible posteriorly to overlap the distal segment (ramus) as a means of reducing the prognathism. There are a variety of surgical approaches and procedures available to the surgeon. The operations can be done intraorally by making incisions in the facial portion of the oral vestibule. An extraoral approach may be utilized, with a small incision made below the angle of the mandible. An operative procedure to retract the mandible may be done with a vertical oblique osteotomy (see Fig. 20-2A), either by extraoral or intraoral approach, or a sagittal-split osteotomy done intraorally. While other surgical variations are also utilized by some, the procedures noted above are the procedures employed most often.

Advancement of the mandible involves a sagittal-split osteotomy as the procedure of choice (see Fig. 20-2B). The ramus and corpus are split and slid along one another to affect the lengthening of the mandible. It is not common for fixing wires to be required at the surgical site at the ramus-corporis level. The fixation of upper and lower teeth into the acrylic splint provide sufficient stability to permit the area of surgery to heal and solidify in the position created.

When a mandibular or maxillary osteotomy is done, it is often necessary to modify the position of the chin. A genioplasty to either augment or reduce the lower face height and horizontal position of the chin is a common operation, either in isolation or in combination with other procedures. This work can be done intraorally, using a patient's own bone to either slide upon or reduce, or use a graft from another area of the body as a wedge. It can also be done using an extraoral incision below the chin with the implantation of silicone or some other inert implantable material.

Speech Implications from Mandibular Osteotomies

The surgical modification of the position of the lower jaw should also affect a change in the resting posture of the tongue as well as functions of the tongue. Generally, it has been found that an individual's speech adapts quickly and effectively to an osteotomy. On the basis of available clinical evidence, it is not expected that speech should deteriorate following a mandibular osteotomy (or a maxillary procedure either). Individuals who undergo osteotomies, who previous to the operation had normal speech, appear to adapt quite well to a surgically modified oral environment. The patient with abnormal speech patterning preoperatively may spontaneously adapt to a normal speech physiologic pattern but may also require therapy postoperatively.

A case in point is the patient with a skeletal anterior openbite malocclusion. Such a patient may be expected to exhibit a tongue thrust swallow pattern and a cosmetic tongue thrust in speaking. Sibilants may be produced normally or abnormally from an acoustic standpoint prior to surgery. Such a patient has a fairly good prognosis for achieving a nonthrusting pattern following surgery.

The individual with a skeletal openbite is also a good example of biological considerations in the choice of surgical procedure. It is a general rule in orthognathic surgery that anterior skeletal openbites are *not* closed by mandibular osteotomies. Of all the types of osteotomies, a mandibular osteotomy for anterior openbite is subject to more postoperative relapse than almost any other procedure. This is associated with the strong pull of the strap muscles of the neck in fighting the rotational repositioning of the mandible. In most cases, the posterior portion of the maxilla is *impacted* as a means of closing an

anterior openbite. Impaction of the maxilla, either in one piece or with posterior bilateral segmental impactions, permits the mandible to autorotate closed as the upper molar teeth are repositioned superiorly. Autorotation of the mandible is a natural adjustment of the facial skeleton, while rotating the corpus of the mandible relative to the ramus, especially with an elevation of the front of the mandible, is evidently not a normal rotation. Most important, however, is the principle that an operation should be performed in the jaw area where the cause of the problem is located. Most patients with an anterior skeletal openbite have posterior maxillary vertical excess, which is why the maxilla is surgically impacted posteriorly. Of course, many other problems may be evident in a given patient, such as prognathism with an openbite, where the mandible may be implicated as the dysplastic area and, therefore, will be the focus of surgical planning.

While speech is not expected to change significantly in the typical osteotomy patient, positive and negative changes may be seen individually. Some patients may require adaptive speech therapy for a period of time postsurgically, while others

who show adaptive problems immediately after release from intermaxillary fixation may spontaneously improve over time (Figs. 20-9A&B).

One area of potential importance to the speech clinician is the patient with lip incompetence preoperatively. Lip incompetence present over a period of many years may leave the lips rather flaccid following surgery. While the jaws are arranged in a manner compatible with the ability for a natural lip seal, the lip incompetence may be retained in the presence of poor lip tonicity. Some supportive therapy may be indicated for such patients. Currently, measures of lip tonicity, as well as therapeutic measures to provide lip competence, are fairly subjective. Nonetheless, this potential problem is mentioned here as a possible consideration for the clinician working conjointly with a patient who undergoes a mandibular (or maxillary) osteotomy.

While current research has not strongly implicated the speech of the osteotomy patient as significantly deteriorating following any osteotomy, there are a host of considerations yet to be exploited by the speech clinician as to the impact of surgery on speech.

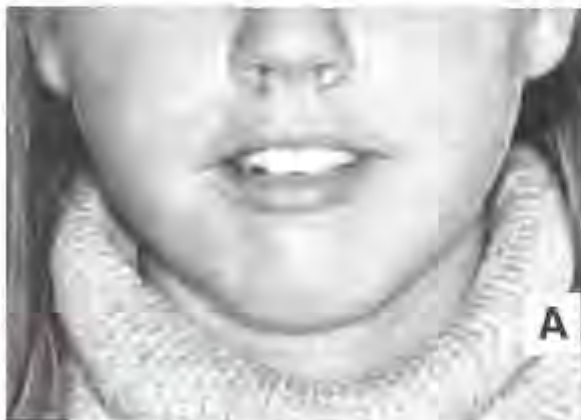

Figure 20-9A. Patient with vertical maxillary excess and lip incompetence pre-operative to a LeFort I maxillary impaction osteotomy.

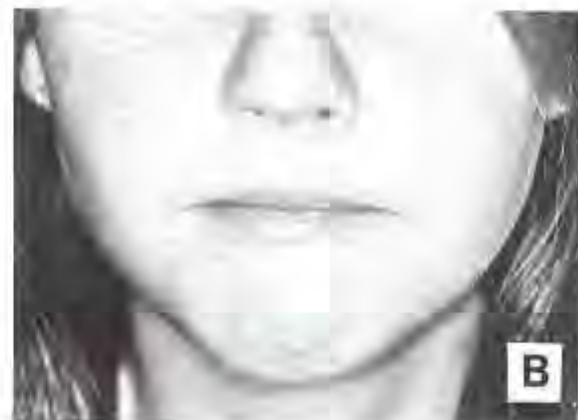

Figure 20-9B. Patient following maxillary impaction. Some lip incompetence remains.

BIBLIOGRAPHY

- Bell, W.H., Proffit, W.R., and White, R.P.: *Surgical Correction of Dentofacial Deformities*, Philadelphia, Saunders, 1980, Vols. I and II.
- Epker, B.N., and Wolford, L.M.: *Dentofacial Deformities: Surgical-Orthodontic Correction*. St. Louis, C.V. Mosby, 1980.
- Epker, B.N., and Wolford, L.M.: Middle third face osteotomies. *J Oral Surg*, 33:491-514, 1975.
- Mason, R.M., Turvey, T.A., and Warren, D.W.: Speech considerations with maxillary advancement procedures. *J Oral Surg*, 38:752-758, 1980.
- Walker, G.F.: A new approach to the analysis of craniofacial morphology and growth. *Am J Orthod*, 61:221-230, 1972.
- West, R., and Epker, B.N.: Posterior maxillary surgery: its place in the correction of dentofacial deformities. *J Oral Surg*, 30:562-575, 1972.